

ASISTENSI III

PRAKTIKUM BIOLOGI VERTEBRATA



Rizka Apriani Putri, M.Sc / FMIPA UNY
rizka_apriani@uny.ac.id

Biologi Vertebrata 2015/2016

Acara 4 : Anatomi dan Morfologi Burung

Acara IV : Anatomi & Morfologi Burung

Pengamatan dan gambar :

- I. Inspectio + Tipe Bulu
- II. Topografi
- III. Systema Respiratorium
- IV. Systema Cardiovasculare
- V. Systema Digestorium
- VI. Systema Urogenitalia
- VII. Skeleton
- VIII. Systema Nervosum

I. Inspectio

A. Caput

1. Rostrum
2. Organon Visus
3. Nares
4. Porus Auditivus/ Auditorius
Externus
5. Cera

B. Truncus

C. Extremitas

Anterior/ Superior

D. Extremitas Posterior/ Inferior

6. Digiti
7. Falcula

E. Cauda

BULU pada Burung : 3 tipe

A. Plumae (Pada ekor dan sayap)

1. Rachis
2. Vexillum
3. Calamus
4. Umbilicus

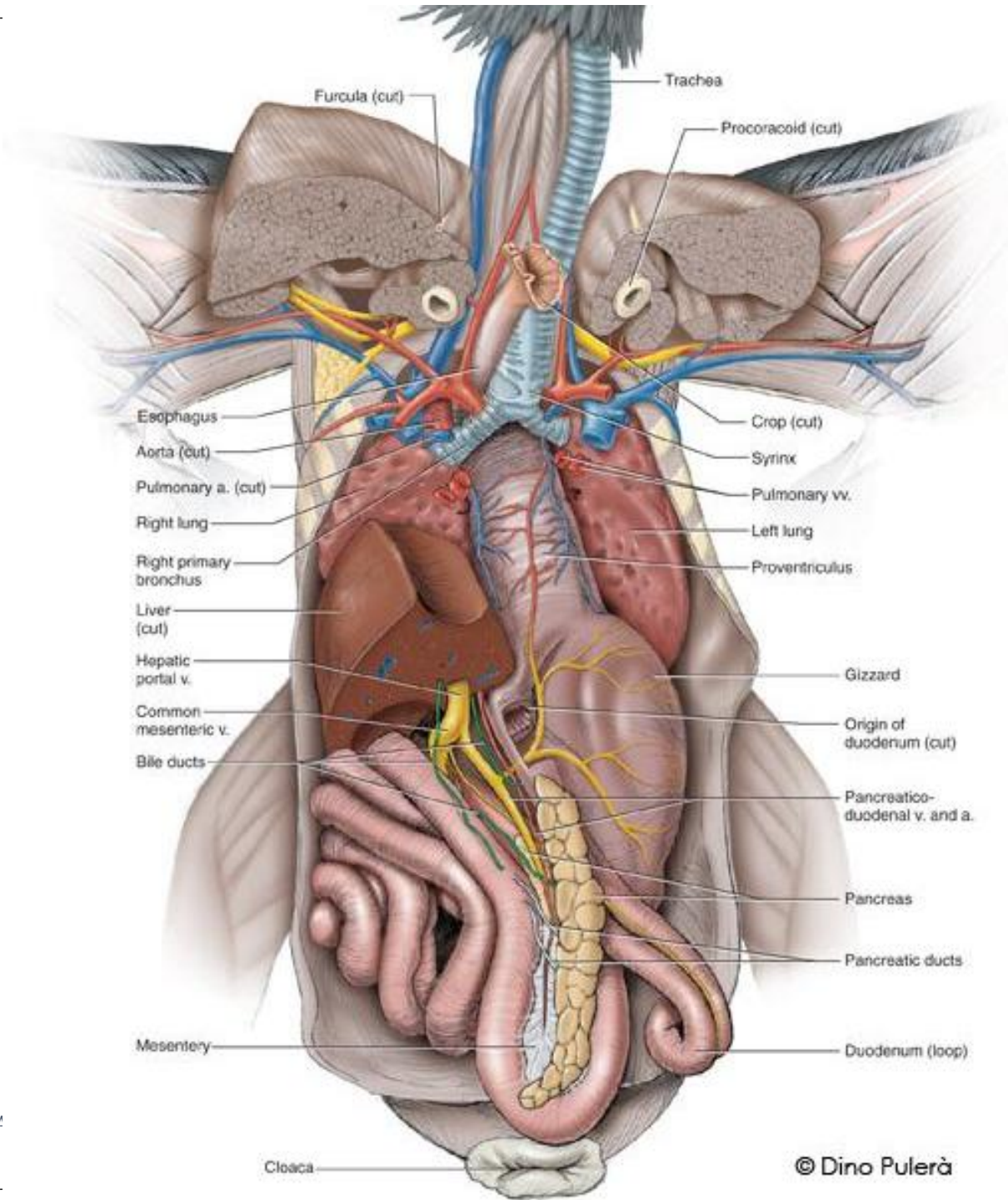
B. Plumulae (tubuh bagian ventral)

5. Barbae

C. Filoplumae (terdapat diantara Plumulae)

II. Topografi

1. Esophagus
2. Ingluvies (Tembolok)
3. Proventriculus (lambung kelenjar)
4. Ventriculus (true stomach/ lambung pengunyah)
5. Intestinum
6. Trachea
7. Pulmo
8. Cor
9. Hepar
10. Lien
11. Gonad
12. Ren
13. Pancreas



III. Systema Respiratorium

1. Trachea

2. Annulus Trachealis

3. Syrinx (Alat suara) → dari luar tidak terlihat, posisi pada **Bifurcatio tracheae**

4. Bronchus

5. Pulmo (menempel pada columna vertebralis dan costae)

IV. Systema Cardiovasculare

1. Atrium Dextrum
2. Atrium Sinistrum
3. Venrikel Dexter
4. Ventrikel Sinister
5. Arcus Aortae (ke arah kanan)
6. Arteria Carotis Communis
7. Arteria Subclavia
8. Arteria Pectoralis

V. Systema Digestorium

A. Tractus Digestivus

1. Esophagus
2. Ingluvies
3. Proventriculus
4. Ventriculus
5. Intestinum Tenue
6. Intestinum crassum
(terdapat penonjolan kekanan dan kiri, disebut Bursa Fabricius)
7. Rectum

B. Glandula Digestoria

8. Hepar
9. Pancreas

VI. Systema Urogenitalia

Organa Uropoetica

1. Ren (Metanephros)
2. Ureter
3. Cloaca

Organa Genitalia

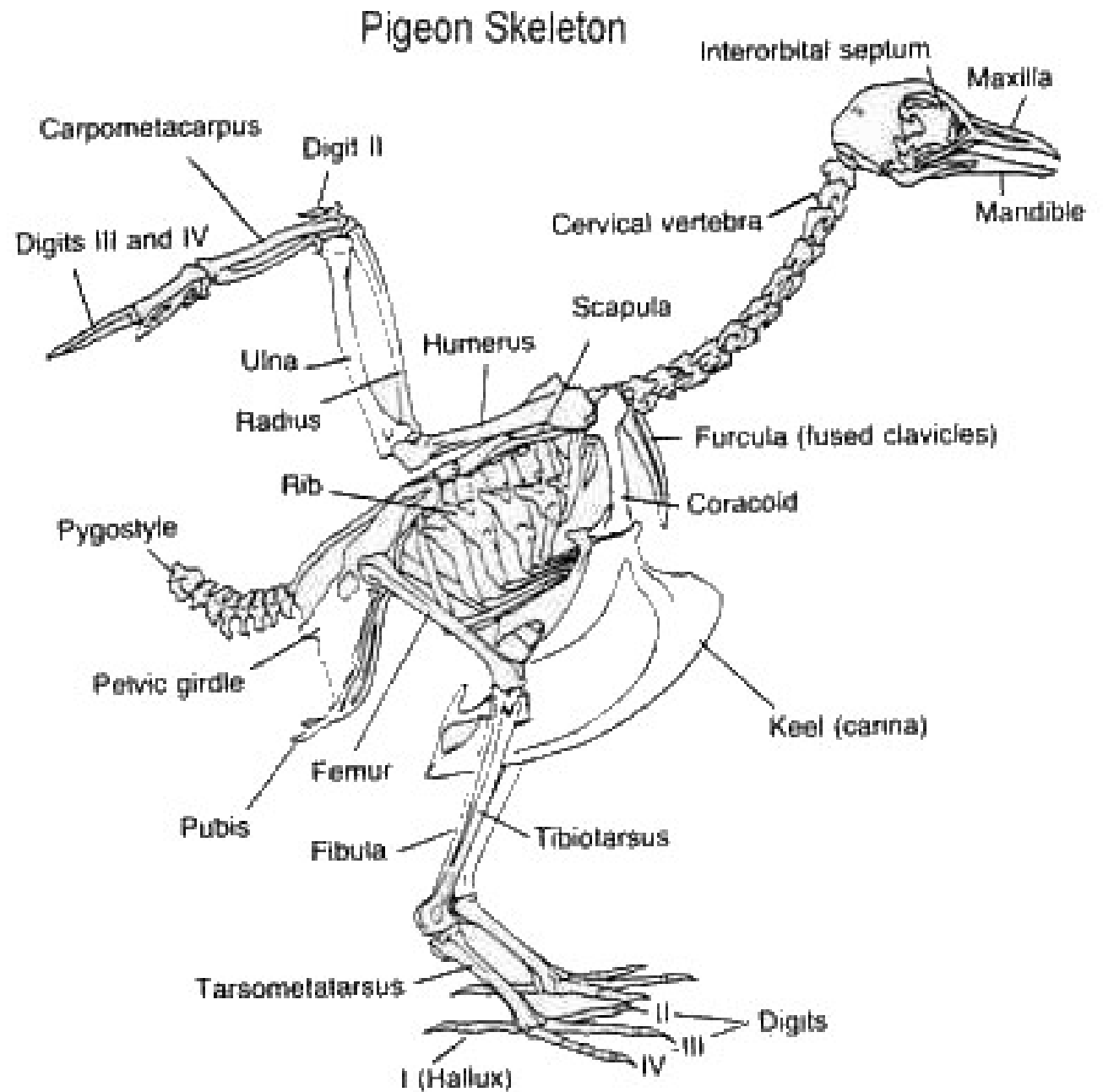
Masculina (♂)

4. Testis
5. Ductus Epididymis
6. Vas Deferens

Feminina

4. Ovarium
5. Infundibulum
6. Oviduct
7. “uterus”

VII. Skeleton



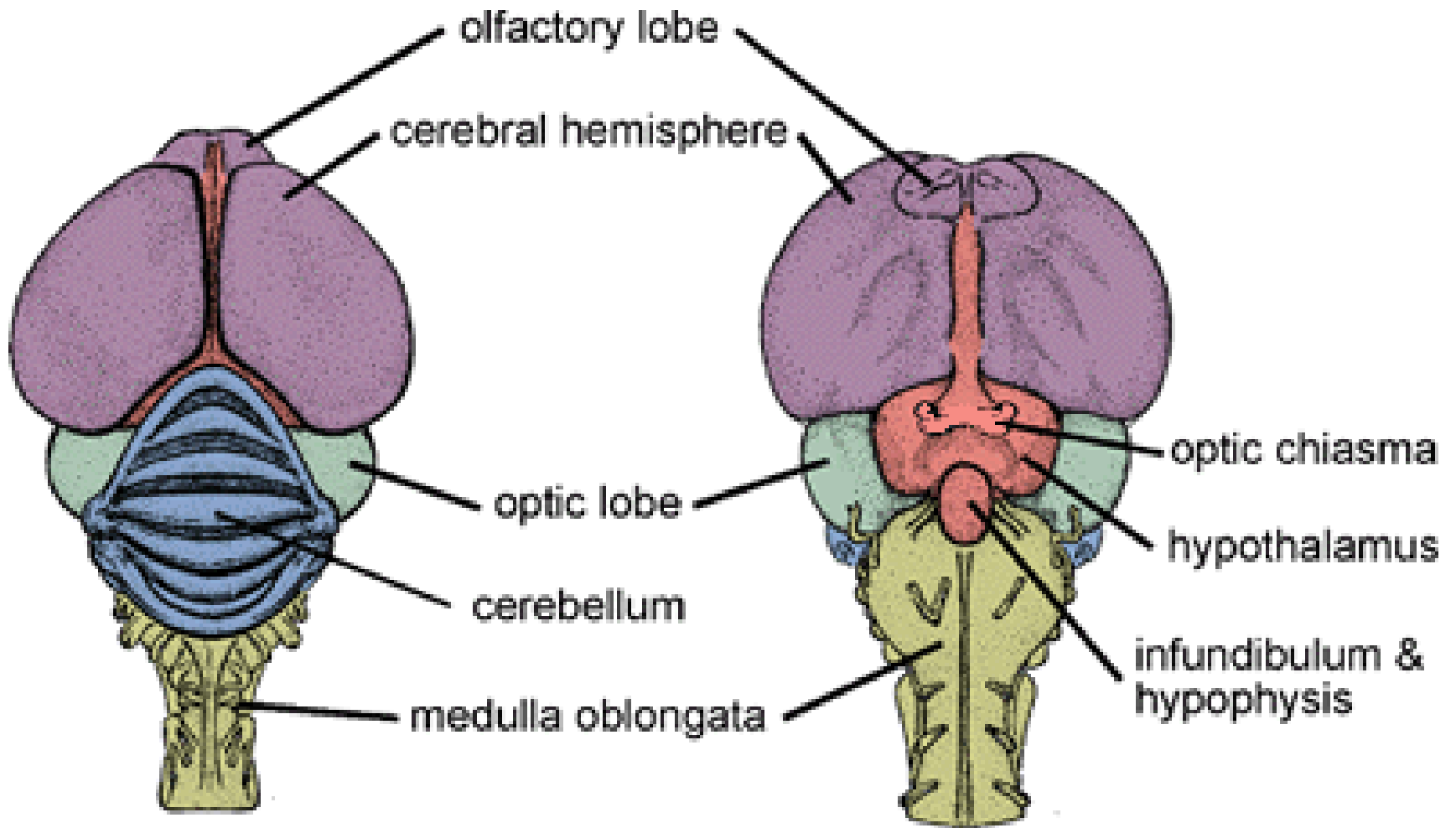
VIII. Systema Nervosum

Facies Dorsalis

1. Lobus Olfactorius
2. Hemisphaerium Cerebri
3. Lobus opticus
4. Medulla Oblongata
5. Cerebellum

Facies Ventralis

6. Chiasma Nervi optici
7. Hypophysis



Dorsal View

Ventral View

ACARA 5 : Anatomi & Morfologi Marmut

Acara V : Anatomi & Morfologi Marmut

Pengamatan dan gambar :

- I. Inspectio
- II. Topografi
- III. Systema Respiratorium
- IV. Systema Cardiovasculare
- V. Systema Digestorium
- VI. Systema Urogenitalia
- VII. Skeleton
- VIII. Systema Nervosum

I. Inspectio

A. Caput

1. Rima Oris
2. Organon Visus
3. Nares
4. Porus Acusticus Externus
5. Auriculae
6. Vibrissae

B. Truncus

C. Extremitas Anterior

7. Brachium
8. Antebrachium
9. Manus
10. Digiti

D. Extremitas Posterior

11. Femur
12. Crus
13. Pes

II. Topografi (Situs Viscerum Thorachis et Abdominis)

1. Esophagus
2. Trachea
3. Pulmo
4. Diafragma
5. Ventriculus
6. Intestinum Tenue
7. Coecum
8. Intestinum Crassum
9. Hepar
10. Vesica Fellea
11. Pancreas
12. Ren (metanephros)
13. Glandula Suprarenalis
14. Gonad
15. Lien

III. Systema Respiratorium

1. Epiglottis
2. Trachea
3. Bifurcatio tracheae
4. Bronchus
5. Pulmo (5 lobi)

IV. Systema Cardiovasculare

1. Atrium Dextrum
2. Atrium Sinistrum
3. Venrikel Dexter
4. Ventrikel Sinister
5. Arcus Aortae
6. Arteria Carotis Communis
7. Arteria Subclavia
8. Aorta dorsalis

V. Systema Digestorium

A. Tractus Digestivus

1. Esophagus
2. Ventriculus
3. Intestinum Tenue
4. Coecum
 - a. Taenia
 - b. Haustra
 - c. Incisura
5. Intestinum crassum
7. Rectum
8. Anus

B. Glandula Digestoria

8. Hepar
9. Vesica Fellea
10. Pancreas
11. Ductus Choledocus
(saluran tempat bersatunya
duktus cysticus dan d.
hepaticus)
12. Ductus Hepaticus
(saluran dr Hepar)
13. Ductus Cysticus (saluran
dari v. fellea)

VI. Systema Urogenitalia

Organa Uropoetica

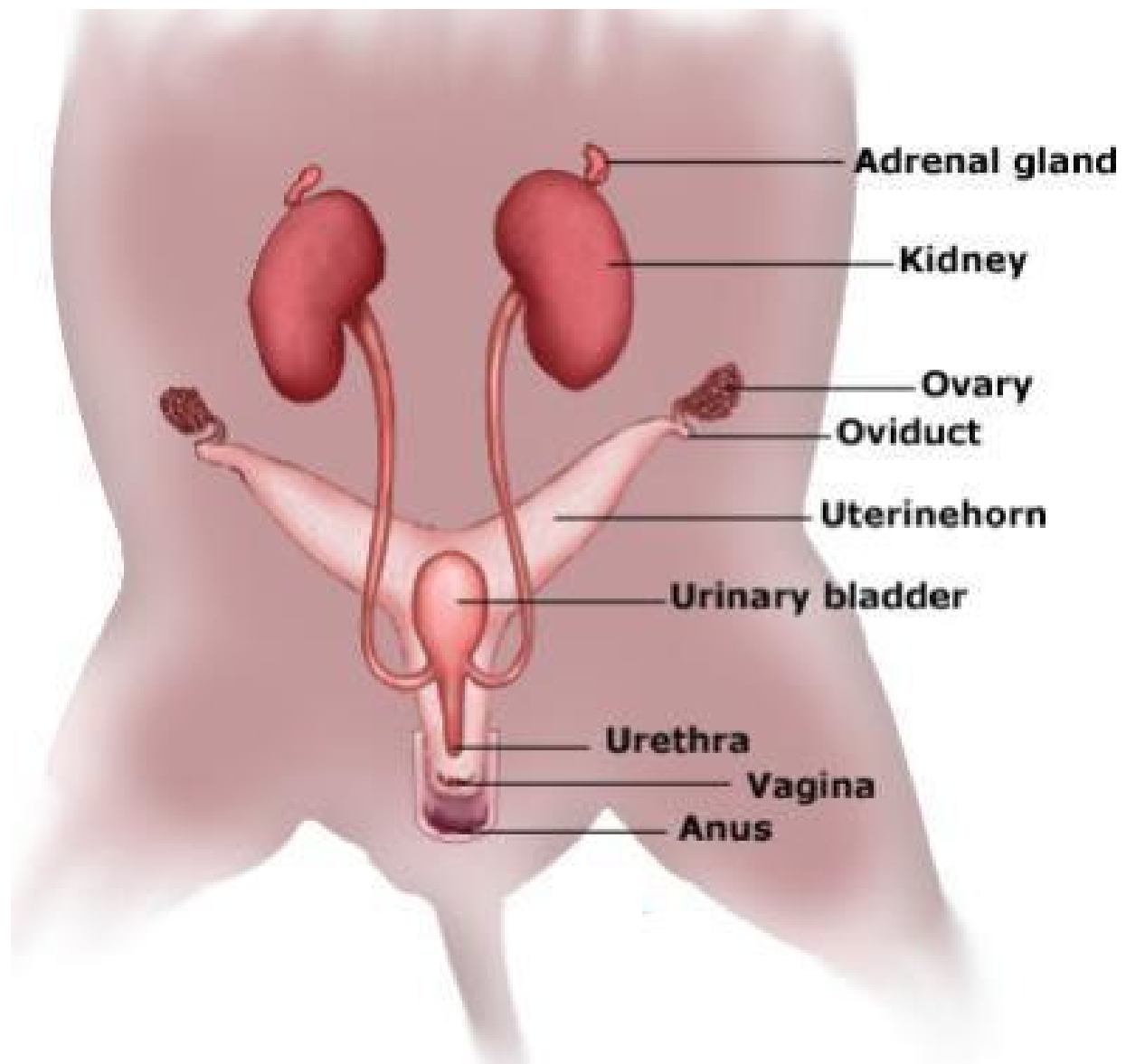
1. Ren
2. Ureter
3. Vesica Urinaria
4. Urethra

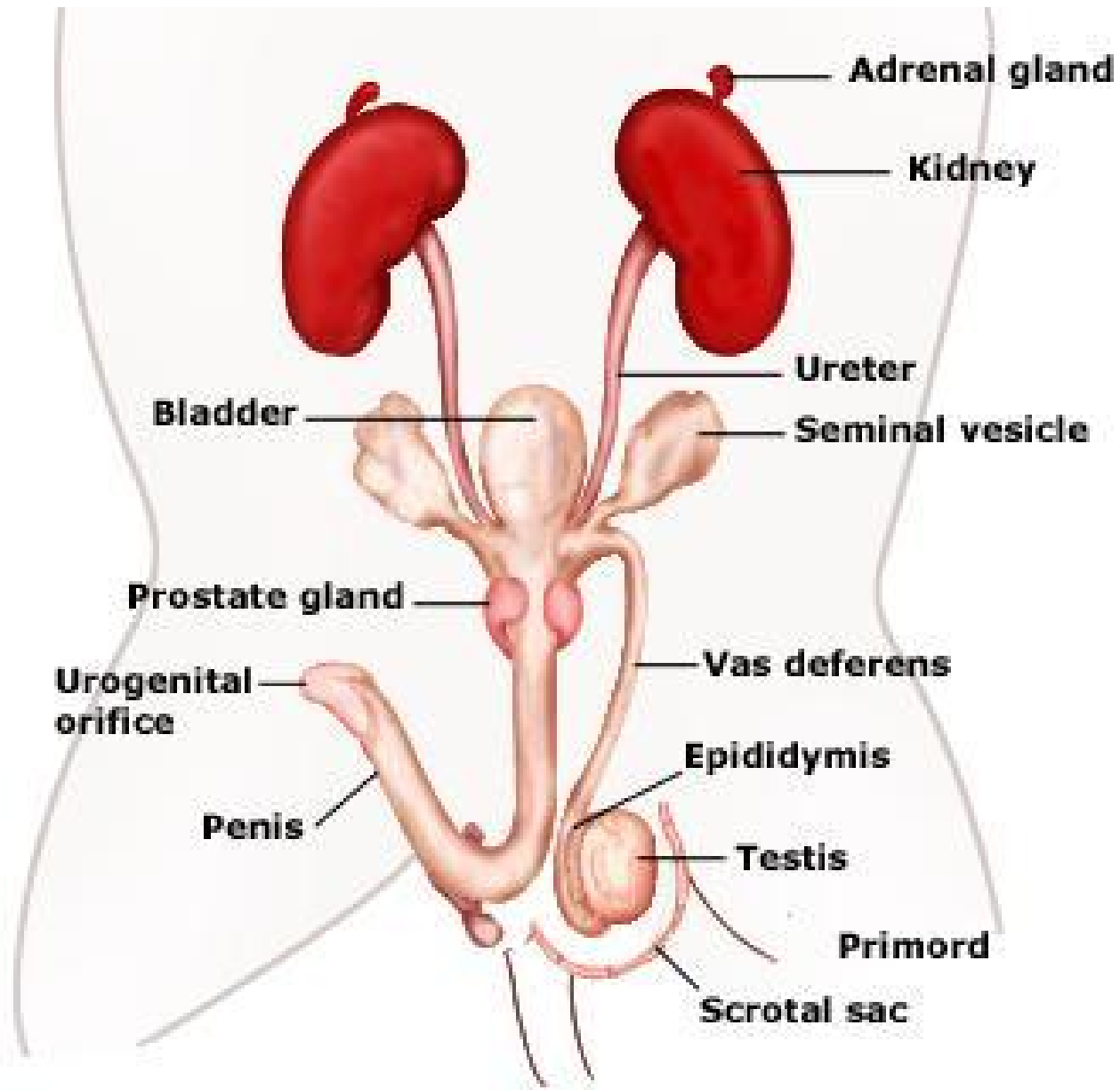
Organa Genitalia Masculina (♂)

5. Testis
6. Corpus Adiposum
7. Epididymis
8. Ductus Deferens
9. Vesicula Seminalis/ uterus
masculus

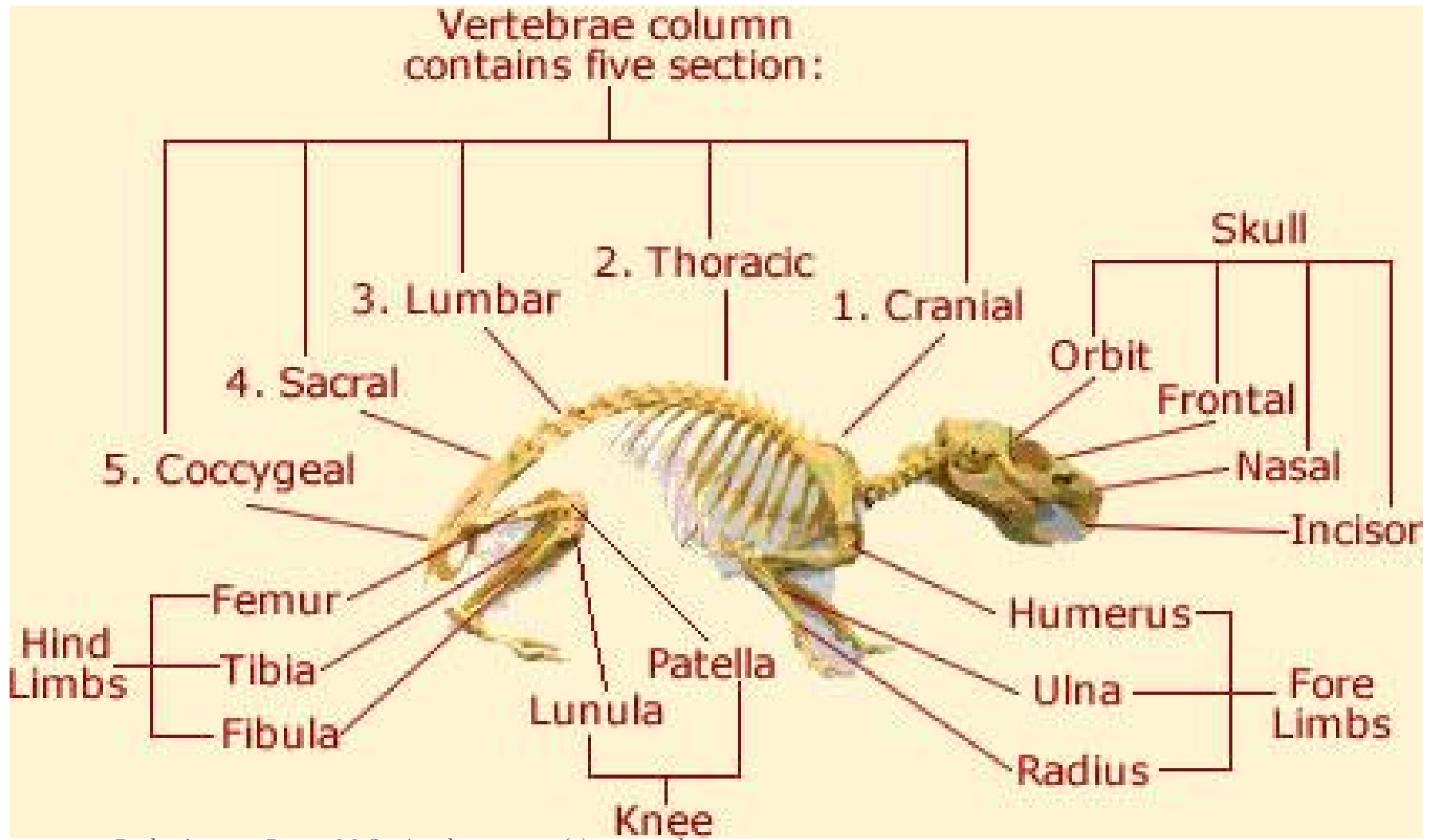
Feminina

5. Ovarium
6. Infundibulum
7. Oviduct
8. Uterus





VII. Skeleton



Rizka Apriani Putri, M.Sc / rizka_apriani@uny.ac.id

VIII. Systema Nervosum

Facies Dorsalis

1. Bulbus Olfactorius
2. Hemisphaerium Cerebri
3. Fissura Longitudinale
4. Corpora Quadrigemina
5. Cerebellum
6. Flocculus
7. Medulla Oblongata

Facies Ventralis

8. Chiasma Nervi optici
9. Hypophysis

Rizka Apriani Putri, M.Sc / rizka_apriani@uny.ac.id

